The AI Revolution in Healthcare
How Dr.AI Integrates AI with Medical Expertise

Clarence Liao, M.D.

Resident, Fellowship & Attending Physician, Cathay General Hospital 1995 - 2007
Mayo Clinic, Rochester, MN 2001-2002
International Committee Member, ASGE 2003-2004
National Cancer Center, Tokyo 2007
LIAO Clinic 2007-
IntoWell Biomedical Technology 2011-
MEIYU Clinic 2012-

Table of Contents

1. Company Introduction

Company Introduction

Company Name:	IntoWell Biomedical Technology, Inc.
Established:	August 29, 2011
Market Cap:	7,711,138 USD
Business Activities:	• Provision of AI-driven health solutions • Operation of clinics and health Exam centers • Consulting and planning for health exam centers at medical institutions • Health exam center development and management services

2. Dr.AI for Healthcare Professionals

Dr.AI

Empowering Healthcare Professionals

Dr.AI supports and reinforces the power of healthcare professionals through the following six advantages.

- Advanced data analysis capabilities
- Assured Quality
- Proactive Health Predictions
- Personalized Treatments
- Collaborative Healthcare
- Evidence-Informed Recommendations

Protection of Personal Information and HIPAA Compliance

It is not required to input personally identifiable information (such as name, ID, or date of birth) when utilizing our services. All of our services are fully compliant with HIPAA regulations.

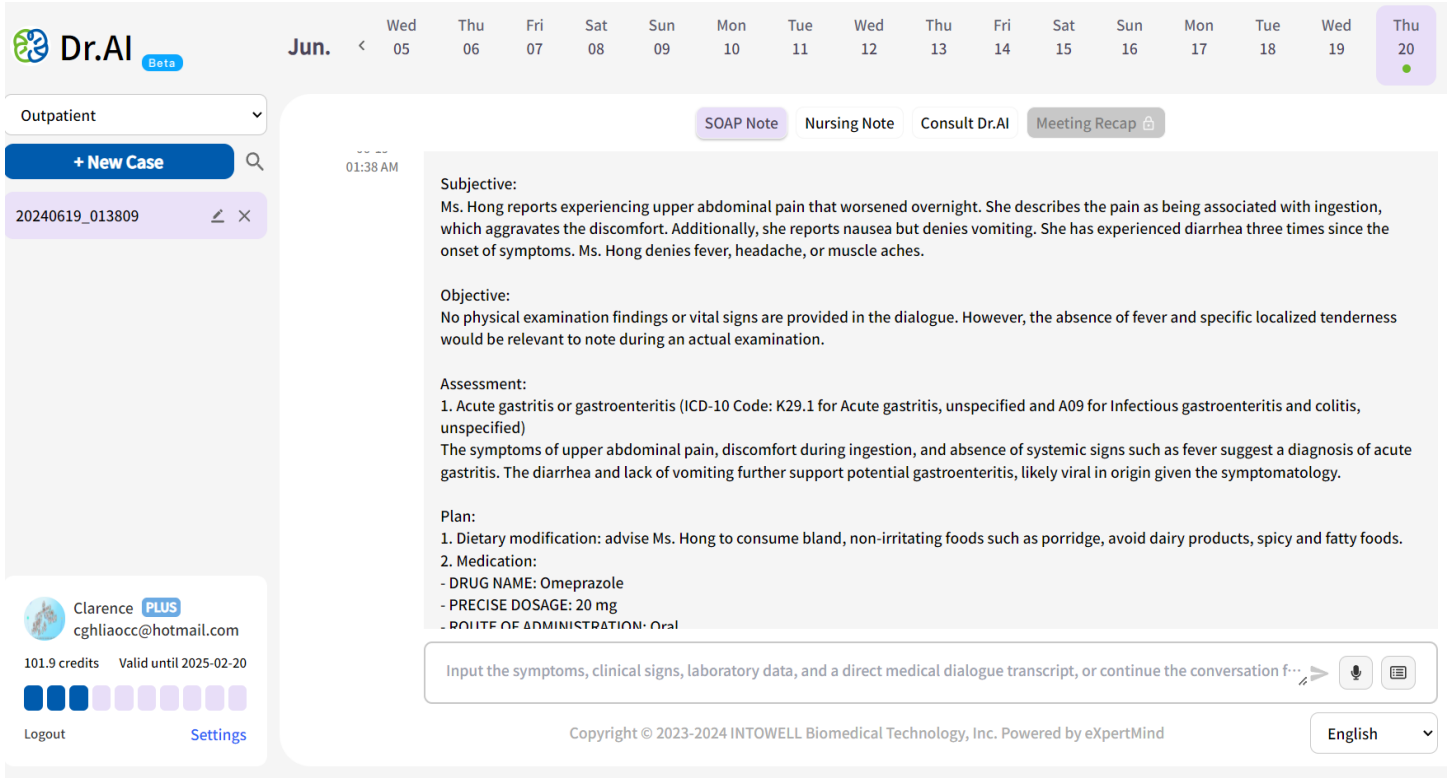

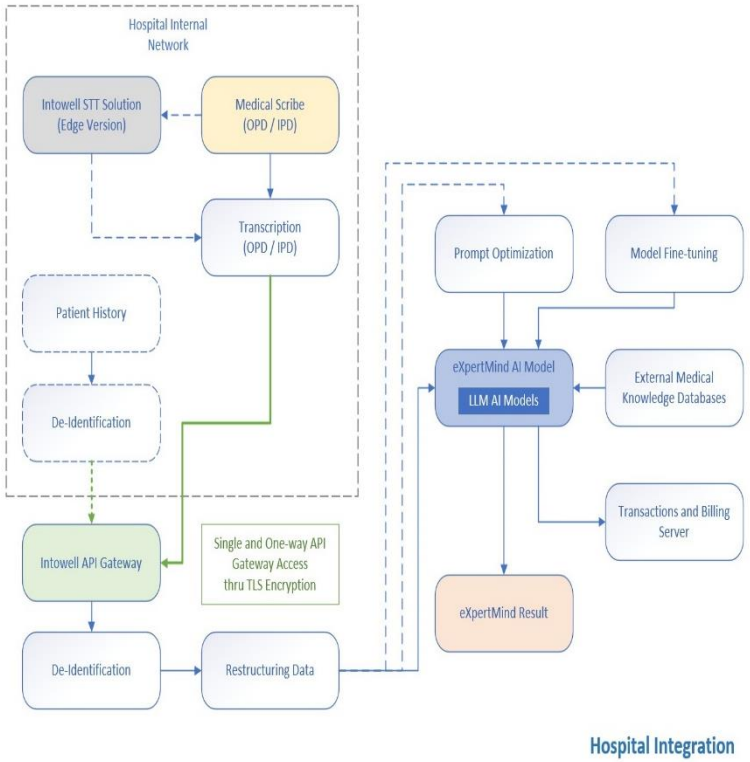

Dr.AI's Revolutionary Features for Smart Hospitals

Dr.AI

1. Patient Admission

• **Registration**:

Collect demographics, insurance info, and medical history.

A. Dr.AI MedPA:
Patients verbally provide initial subjective info and symptoms at check-in, which is then transferred to the outpatient doctor's workstation.

B. Dr.AI CPMP:
Collects demographics, insurance, and medical history, ensuring accurate data intake.

• **Triage**:

Assess the severity of the patient's condition to prioritize care.

C. Dr.AI Integrated Analysis:
Integrates admission notes, captures detailed patient info, and automates initial treatment orders based on this data and clinical guidelines.

2. Initial Assessment

• **Initial Evaluation**:

A. Dr.AI Admission Note - Assessment and Plan:
Conducts a comprehensive assessment (vital signs, medical history, physical exam, patient complaints, lab results) to generate a tailored POMR (Problem-Oriented Medical Record).

• **Initial Orders**:

B. Dr.AI Admission Orders:
Automatically generates initial treatment orders (admission orders) for nursing care based on patient data and clinical guidelines.

3. Diagnosis & Planning

• **Diagnostic Testing, Diagnosis, and Treatment Plan**

A. Dr.AI's SOAP Notes:
Structured treatment plan (Subjective, Objective, Assessment, Plan) aiding in accurate diagnosis for outpatient care.

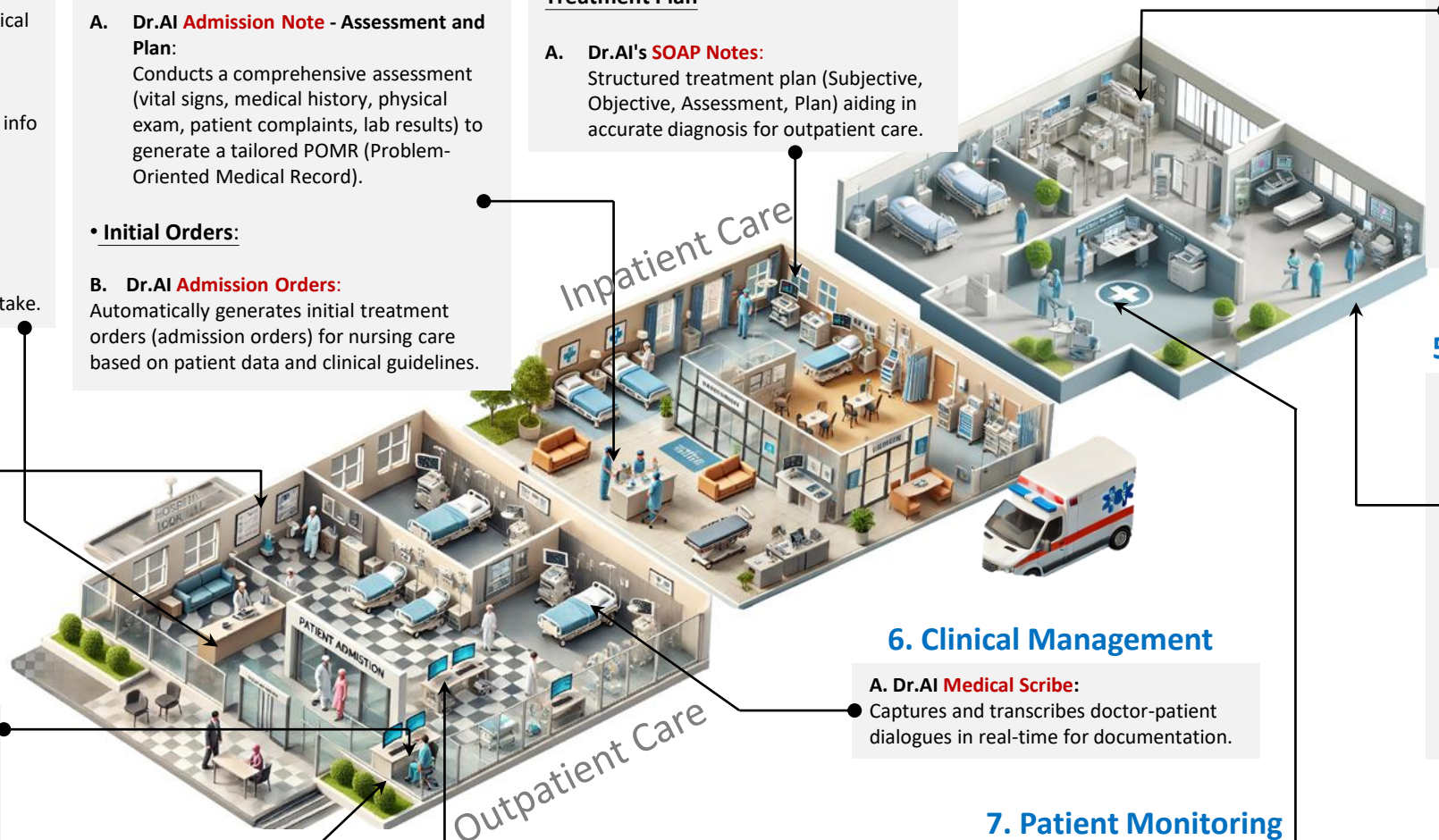

4. Treatment

• **Implementation and Monitoring of Treatment Plan**:

A. Dr.AI Pharmacotherapy:
Provides personalized medication plans based on thorough analysis, including side effects and monitoring parameters.

B. Dr.AI Cancer Strategies:
Uses advanced algorithms to create optimal treatment plans for oncology patients.

5. Ongoing Assessment & Care

• **Progress Notes**:

A. Dr.AI Progress Notes:
Continuous documentation of patient status and response to treatments for real-time updates.

• **Multidisciplinary Team Meetings:**

B. Dr.AI Meeting Recaps:
Automatically generates meeting summaries, ensuring clear communication and alignment on care plans.

6. Clinical Management

A. Dr.AI Medical Scribe:
Captures and transcribes doctor-patient dialogues in real-time for documentation.

7. Patient Monitoring

A. Dr.AI Progress Notes:
Continuous documentation of patient status for real-time updates.
B. Dr.AI Nursing Notes:
Detailed nursing documentation with global standard formats for consistent care.

8. Discharge Planning

A. Dr.AI Consult Dr. AI:
Generates discharge instructions and follow-up plans, ensuring patient education and care adherence.

9. Follow-Up Care

A. Dr.AI Router MoAI :
Integrated with telemedicine, allowing patients to verbally record their recovery status for backend real-time updates on patient recovery.

10. Health Exam Center

A. Dr.AI MedExam Pro:
Dr.AI's Health Exam Report System boosts efficiency with its One-Click Mass Report Generation feature, streamlining workflows and enhancing precision.

2-1 For Inpatient Care

Accuracy ①: Analysis of 16 Emergency Cases at Yale School of Medicine

Judging from the analysis results of 16 cases by Dr.AI
Dr.AI's capability has reached the level of an attending physician.

Analysis Data :

Present illness, Physical exam, with Lab. Tests

https://medicine.yale.edu/intmed/education/medstudent/intmedclerkship/cases/)

Analysis Result : Grade 5 - Attending Physician

- Sensitivity of tentative diagnosis (**with** Lab. tests) : **100**
- Average score: **95** of 100
- Professional grade in medicine: **4.75** (>4.5)

Scoring by Attending Physicians:
(0-20 for each item, and a total of 100)

- Clinical Acumen
- Diagnostic Reasoning
- Treatment Planning
- Risk Assessment and Anticipation of Complications
- Communication Skills

Professional Grade in Medicine:

Level 5 :	Attending Physician	(**4.5-5**)
Level 4 :	Fellow	(3.5-4.4)
Level 3 :	Resident	(2.5-3.4)
Level 2 :	Intern	(1.5-2.4)
Level 1 :	Medical Student	(1-1.4)

Accuracy ②: Analysis of 36 Cases by MSD Pharmaceuticals

- **A total of 36 case reports and Resource:**
  - MSD Manual (professional version)
    https://www.msdmanuals.com/professional/pages-with-widgets/case-studies?mode=list
- **Analysis data: Present illness, Physical exam**
  - Sensitivity of tentative diagnosis (without Labs): **86%**
  - Sensitivity of subsequent diagnosis (with subsequent 1st Labs): **97%**

Dr.AI vs. Competitor

16 Patients' Admission Note from Yale Scehool of Medicine

https://medicine.yale.edu/intmed/education/medstudent/intmedclerkship/cases/

Analyze with AI-empowered diagnostic tools

Admission Note with Labs	Dr.AI (eXpertMind)	Medical Chat (ChatGPT)
True positive rate (Sensitivity)	**100%**	78%

36 Patients' Admission Note from MSD Manual Professional Edition

https://www.msdmanuals.com/professional/pages-with-widgets/case-studies?mode=list

Analyze with AI-empowered diagnostic tools

Admission Note without Labs	Dr.AI (eXpertMind)	Medical Chat (ChatGPT)
True positive rate (Sensitivity)	**86%**	61%
Admission Note with Labs		
True positive rate (Sensitivity)	**97%**	

Subspecialities for Analysis

1. CV
2. Nephrology
3. GI
4. Neurology
5. Chest
6. Hematology
7. Infection
8. Endocrine
9. Orthopedics
10. Pediatric
11. Urology
12. Gyn & Obs

Challenges in Existing Inpatient Care

Dr.AI offers various solutions to address the following issues in inpatient care:

- Shortage of residents and physician assistants
- High cost of training physicians and assistants
- Blind spots in medical care

- High pressure on on-duty physicians and assistants
- Time-consuming and error-prone documentation work
- inconsistent quality of medical records

Leveraging an Inpatient Case Report from the Yale School of Medicine

A 52-year-old woman was admitted to the hospital because of increased abdominal girth. About two months prior to admission she noted unexpected weight gain of 10 lbs. This was followed by ankle swelling when she stood up for long periods, and progressed to the point that her clothes became too tight. She said it felt like she was pregnant.

Over the course of the last two weeks she noted increased fatigue, more difficulty sleeping and dyspnea on exertion. Today she claimed that her abdomen and shoulders hurt so she sought medical attention. She has a history of alcohol abuse over the past 20 years, and was hospitalized once for pancreatitis related to alcohol, but had no history of liver disease. She denied any chest pain, cough, change in bowel habits, jaundice, vaginal or rectal bleeding. She lives with her husband and has three healthy children. She has no family history of similar problems; her parents both died of heart disease.

P.E. reveals a thin woman with protuberant abdomen in mild respiratory distress. T 99oF; P 100; R 30; BP 120/80. SKIN - normal but with scattered spider angiomata. LN - none palpable. HEENT - conjuctivae normal; FUNDI - normal; oropharynx dry without lesions. CHEST - clear with decreased breath sounds at both bases about 1/4 way up; percussion note is dull over the same area and there is an absence of tactile fremitus at both bases. COR - JVP is 6 cm; RRR with no murmurs, gallops or rubs audible. ABD - protuberant but symmetrical on inspection; there are no palpable masses; liver and spleen are not palpable-; there is mild tenderness throughout but no rebound pain; flank dullness and fluid wave are evident; BS are diminished but present. G/R - speculum exam is normal; rectum is normal; stool heme negative. NEURO - nonfocal. EXTREMITIES - 2+ edema.

LABS: Na 128, K 3.2, Cl 107, HCO3 17, BUN 4, Cr 0.5, glu192
Hb 13.0, Hct 39.0, WBC 10.5 (normal differential), plts 143 K
UA: clear/1.010/1+ protein; no glucose, ketones, cells or casts
EKG: NSR 100/nl intervals/no ST-T wave changes
CXR: bilateral pleural effusions; normal heart size

Comprehensive Analysis for Resident Physician

Comprehensive analysis generated by Dr.AI

1. **Differential Diagnosis:**
   (1) Cirrhosis: Considering the chronic alcohol abuse, ascites, spider angiomata, and bilateral pleural effusions, cirrhosis is highly likely.
   (2) Congestive Heart Failure (CHF): The JVP elevation, bilateral pleural effusions, and peripheral edema point towards CHF, though the normal heart size on CXR adds complexity.
   (3) Nephrotic Syndrome: Hypoalbuminemia and proteinuria suggest nephrotic syndrome, but it is less plausible given other findings that more strongly suggest alternative diagnoses.

2. **Additional Information Required:**
   (1) Clarification on the extent and pattern of alcohol consumption to further corroborate the likelihood of cirrhosis.
   (2) Assessment of cardiac function, such as an echocardiogram, to rule in or out CHF.
   (3) Renal function tests and serum albumin measurements for a thorough evaluation of nephrotic syndrome.

3. **Most Likely Diagnosis:**
   Cirrhosis, with supporting evidence from the protuberant abdomen with fluid wave, spider angiomata, hypoalbuminemia, and extensive alcohol use history. Cirrhosis diagnosis can be further substantiated by a paracentesis demonstrating a serum-ascites albumin gradient (SAAG) greater than 1.1 g/dL, indicative of portal hypertension.

4. **Host Factors:**
   The patient's long-standing alcohol abuse is a major contributing factor to liver damage and the possible development of cirrhosis.

5. **Presumed Pathogenesis:**
   Prolonged alcohol intake causes liver injury, which progresses to inflammation and fibrosis, ultimately leading to cirrhosis and the associated disruption of hepatic blood flow and portal hypertension.

6. **Additional Diagnostic Tests:**
   Assays such as liver function tests, coagulation profile, and ascitic fluid analysis following a diagnostic paracentesis are fundamental prior to treatment.

7. **Imaging Studies:**
   An abdominal ultrasound with Doppler is warranted to evaluate liver structure, portal blood flow, and check for complications including hepatocellular carcinoma.

8. **Urgent Treatment:**
   Ascites management with sodium restriction and diuretics, namely spironolactone and furosemide. Tense ascites necessitating respiratory relief may require therapeutic paracentesis.

9. **Pharmacologic Therapy:**
   Administer spironolactone and furosemide to manage fluid overload. Monitor therapeutic efficacy by tracking daily weights, abdominal girth, and electrolyte and renal function tests.

10. **Potential Complications:**
   The patient may develop hepatic encephalopathy, spontaneous bacterial peritonitis (SBP), or hepatorenal syndrome. Early indicators such as cognitive changes could suggest impending hepatic encephalopathy.

11. **Preventive Measures:**
   Maintaining total abstinence from alcohol is essential. Ongoing care with a hepatologist, nutritional counseling, and consideration for liver transplantation if criteria are met will be necessary.

Admission Note and Order Generated by Dr.AI (1)

Chief Complaint:
Increased abdominal girth and associated symptoms.

Present Illness:
A 52-year-old woman with a significant alcohol intake history has been experiencing progressive abdominal distension over the past two months, accompanied by a 10-pound weight gain. She also reports ankle swelling, particularly after prolonged standing, and an increase in clothing tightness, which she likens to the sensation of pregnancy. Over the past two weeks, her condition has worsened, with escalated fatigue, difficulty sleeping, and shortness of breath upon exertion. She sought medical attention today due to the onset of abdominal and shoulder pain. Her medical history is notable for alcohol abuse and a past hospitalization for pancreatitis, although she denies any known liver disease. The patient's symptomatology does not include chest pain, cough, changes in bowel habits, jaundice, or bleeding. She resides with her spouse and is the mother of three healthy children. There is no reported family history of similar ailments, though her parents both passed away from heart disease.

Past Medical History:
Medical history includes alcohol abuse and pancreatitis.
No surgical history reported.
No current medications.
No known drug allergies.
Family history is significant for heart disease leading to the death of both parents; no hereditary illnesses reported.
Social history is notable for long-term alcohol use.

Review of Systems:
General: Recent weight gain, fatigue.
HEENT: Dry oropharynx, otherwise unremarkable.
Cardiovascular: Elevated JVP, regular rate and rhythm.
Respiratory: Decreased breath sounds, dullness to percussion, and absent tactile fremitus at lung bases.
Gastrointestinal: Protuberant abdomen with mild tenderness and signs of ascites.
Musculoskeletal: 2+ pitting edema in the extremities.

Physical Examination:
General appearance: Thin woman appearing in mild respiratory distress.
Skin: Normal with presence of spider angiomata.
HEENT: Conjunctivae and fundi normal.
Chest: Bilateral decreased breath sounds with dullness on percussion.
Cardiovascular: JVP elevated at 6 cm, no murmurs appreciated.
Abdomen: Protuberant, symmetrical, liver and spleen non-palpable, positive fluid wave consistent with ascites.
Neurological: Neurological examination non-focal.

Labs and Diagnostic Studies:
Sodium 128 mmol/L, Potassium 3.2 mmol/L, Chloride 107 mmol/L, Bicarbonate 17 mmol/L, BUN 4 mg/dL, Creatinine 0.5 mg/dL, Glucose 192 mg/dL.
Hemoglobin 13.0 g/dL, Hematocrit 39.0%, White blood cell count 10.5 K/uL, Platelets 143 K/uL.
Urinalysis shows specific gravity of 1.010, protein 1+.
EKG demonstrates normal sinus rhythm at 100 bpm with normal intervals.
Chest X-ray reveals bilateral pleural effusions with a normal cardiac silhouette.

Admission Note and Order Generated by Dr.AI (2)

Assessment and Plans:
1. Ascites likely due to cirrhosis:
Subjective: Complaints of abdominal distension and discomfort.
Objective: Protuberant abdomen, presence of spider angiomata, positive fluid wave test, lab abnormalities indicative of potential liver dysfunction.
Assessment: Ascites likely secondary to cirrhosis (ICD-10 K70.31).
Plan: Order abdominal ultrasound with Doppler to assess for liver cirrhosis and portal hypertension, initiate diuretic therapy with Spironolactone and Furosemide, restrict dietary sodium intake, schedule paracentesis if indicated by symptoms and ultrasound findings, and monitor weight and abdominal girth closely.

2. Alcohol-related liver disease:
Subjective: Long-standing history of substantial alcohol consumption.
Objective: Signs on ph3ysical examination and lab findings suggest chronic liver injury.
Assessment: Alcohol-related liver disease (ICD-10 K70.9).
Plan: Advise the patient to abstain from alcohol entirely, provide nutritional support, order a comprehensive liver panel including alpha-fetoprotein, check for viral hepatitis serologies, and refer to hepatology for further management.

3. Differential diagnosis including heart failure and nephrotic syndrome:
Subjective: Reports of dyspnea on exertion and ankle swelling.
Objective: Clinical findings of peripheral edema and pleural effusions on imaging.
Assessment: Differential diagnosis to include congestive heart failure (ICD-10 I50.9) and nephrotic syndrome (ICD-10 N04.9), though these are considered less likely.
Plan: Proceed with an echocardiogram to evaluate cardiac function if clinical evaluation deems necessary, renal function tests, and check serum protein levels to rule out cardiac or renal causes of edema and effusion.

Admission Orders:

1. Admit to Med/Surg under the care of Dr. [Attending Physician].
2. Tentative Diagnosis:
   - New/Acute Problems: Ascites likely due to cirrhosis (ICD-10 K70.31).
   - Chronic Problems: Alcohol-related liver disease (ICD-10 K70.9).
3. Condition: Guarded.
4. Vitals: Monitor every 4 hours; notify if SBP <90 or >150, HR <60, RR <10, T >38.3°C.
5. Activity: Bed rest with bathroom privileges.
6. Nursing Instructions:
   - Strict intake and output monitoring, obtain daily weights.
   - Administer oxygen as needed, perform neurological checks every 4 hours.
   - Implement fall precautions.
   - Follow the hypoglycemia protocol as needed.
7. Diet: Low sodium diet.
8. Allergies: No known al3lergies.
9. Laboratory studies: Comprehensive liver panel, coagulation profile, serologies for viral hepatitis.
10. Diagnostic studies: Abdominal ultrasound with Doppler, echocardiogram based on further clinical indications.
11. IV Fluids: Normal saline at 100 cc/hr unless contraindicated.
12. Specialists or consults: Request hepatology consultation.
13. Medications:
   - Diuretics: Spironolactone 100 mg orally once daily, Furosemide 40 mg orally once daily.
   - Multivitamin one tablet orally once daily.
   - Thiamine 100 mg orally once daily.
   - Continue: None specified.
   - Discontinue: Discontinue all non-essential medications.

Generated from the Voice Recording of an Inpatient Consultation at the Clinic Through Dr.AI Medical Scribe

Ms. Lee, a 43-year-old patient. Hello Ms. Lee, what seems to be the problem this time? Recently, I've been feeling very tired, get easily short of breath when walking, and mainly my stools have become thin and I feel like I can't completely empty my bowels, like there's always something left. So you mentioned feeling more tired; how long has this been happening? About four months. In addition to the changes in bowel habits over these four months, have you noticed blood in the toilet or on the toilet paper? We use a bidet at home, so I don't usually wipe and haven't noticed any blood. Have you experienced any weight loss? My abdomen feels very bloated, and I get full easily, especially in the lower left area, which feels dull and uncomfortable. This makes me not want to eat, and I've lost some weight, but I'm not sure how much. Has your fatigue affected your work? Yes, I get short of breath just walking and can't climb stairs. I feel drowsy and want to sleep all the time. Any other symptoms? I have a poor appetite and sometimes feel nauseous. Is there any family history of diseases, like cancer? No, no significant family medical history. I had a check-up at another clinic where the doctor examined my rectum and said everything was fine. Any other medical history? No. Given your symptoms over the past four months, I may need to conduct some basic physical examinations. Let's check your eyes first. Your eyelids look a bit anemic. Yes, it seems you have anemia. Now, let's listen to your heart. Your heartbeat is quite fast. Yes, I've been feeling palpitations recently. It appears you might have severe anemia. Your heartbeat is fast, but there are no heart murmurs. Let's check your abdomen. Does it hurt here on the lower left side when I press? Yes, right there, it feels bloated and slightly painful when pressed. There's no ascites in the abdomen, no enlargement of the liver or spleen, and no edema in your legs. You had a rectal examination at another clinic, and there were no issues, correct? Yes. Given your current condition, we may need to do further tests, including blood tests, to determine the cause of your anemia. Is your menstrual cycle regular? Yes, it's very regular and not particularly heavy, but the flow has decreased in the past few months. We might need to do blood tests, fecal occult blood tests, or colonoscopy and gastroscopy to check for gastrointestinal issues, especially since you've mentioned changes in bowel habits and thinner stools. Okay, a nurse will come to ask you some basic health questions in a moment. Thank you.

Generate Admission Note by Utilizing Medical Scribe Voice Recording Text

Admission Note (1)

Chief Complaint:
Fatigue, shortness of breath on exertion, changes in bowel habits, sensation of incomplete bowel evacuation, bloating, and weight loss.

History of Present Illness:
A 43-year-old female, Ms. Lee, has been experiencing increased fatigue, exertional shortness of breath, and altered bowel habits for the past four months. Her stools have become thinner, and she frequently feels that she has not completely evacuated her bowels. She has not noticed any blood in her stool and uses a bidet regularly. Ms. Lee reports left lower quadrant abdominal bloating, a decrease in appetite, and unintentional weight loss, although she has not quantified the weight change. These symptoms have progressively worsened, affecting her daily activities and work performance.

Past Medical History:
Ms. Lee has no significant medical or surgical history. She is not on any chronic medications and has no known drug allergies. No familial history of cancer is reported. A previous medical evaluation, including a digital rectal examination, was unremarkable.

Generate Admission Note by Utilizing Medical Scribe Voice Recording Text

Admission Note (2)

Review of Systems:
General: Reports fatigue and weight loss.
Cardiovascular: Experiences palpitations.
Gastrointestinal: Notes changes in bowel habits, bloating, decreased appetite, and occasional nausea without vomiting.
Hematologic: Denies any abnormal bleeding or bruising.
Musculoskeletal: No joint pains or muscle weakness.
Neurologic: No history of headaches, dizziness, or syncope reported.
Reproductive: Menstrual cycles are regular but have recently decreased in flow.

Physical Examination:
General: Notable pallor observed.
HEENT: Conjunctiva and palpebral conjunctiva are pale, suggesting anemia.
Cardiovascular: Presence of tachycardia; no murmurs detected.
Abdomen: Tenderness in the left lower quadrant; no signs of rebound or guarding, hepatosplenomegaly, or ascites.
Extremities: No edema noted.
Rectal: Examination not performed at this stage.

Labs and Diagnostic Studies:
- CBC: Results pending.
- FOBT: Results pending.
- ESR/CRP: Results pending.
- Colonoscopy: Scheduled to be performed.

Generate Admission Note by Utilizing Medical Scribe Voice Recording Text

Admission Note (3)

Assessment and Plans:
1. **Possible Colorectal Cancer**
Subjective: Reports changes in bowel habits, sensation of incomplete evacuation, and weight loss.
Objective: Finds left lower quadrant tenderness and exhibits pallor.
Assessment: Colorectal cancer is a leading consideration given the symptoms and signs.
Plan: Arrange CBC, FOBT, and colonoscopy to confirm the diagnosis. Oncology consultation planned following diagnostic confirmation.

2. **Suspected Anemia**
Subjective: Complains of fatigue and palpable pallor.
Objective: Observes pale conjunctiva and elevated heart rate.
Assessment: Probable iron-deficiency anemia, potentially due to gastrointestinal bleeding.
Plan: Await CBC results and consider further iron studies. Commence iron supplementation and investigate the primary cause.

3. **Potential Inflammatory Bowel Disease**
Subjective: Lacks comprehensive data for evaluation.
Objective: Awaiting further information for assessment.
Assessment: Inflammatory bowel disease is possible but currently less likely.
Plan: Await CBC, FOBT, and colonoscopy results. Gastroenterology consultation to be considered if findings support.

Generate Admission Order by Utilizing Medical Scribe Voice Recording Text

Admission order

1. Admit to Med/Surg under the care of Dr. [Attending Physician].
2. Tentative Diagnosis:
   - New/Acute Problems: Possible colorectal cancer (ICD-10 Code: C18.9),
     Suspected iron-deficiency anemia (ICD-10 Code: D50.9).
   - Chronic Problems: None noted.
3. Condition: Guarded.
4. Vitals: Monitor every 6 hours; notify if SBP <90 or >150, HR <60, RR <10, T > 38.3°C.
5. Activity: Bed rest with bathroom privileges.
6. Nursing Instructions: Strict intake/output monitoring, daily weights.
   - Wound care: Not applicable.
   - Respiratory care: Incentive spirometry as tolerated.
   - Precautions: Implement fall precautions.
   - Protocols: Not applicable.
7. Diet: Start with clear liquids as tolerated, advance to regular diet as tolerated.
8. Allergies: No known drug or food allergies.
9. Laboratory Studies: CBC, FOBT, ESR/CRP.
10. Diagnostic Studies: Schedule colonoscopy, CT abdomen, and pelvis.
11. IV Fluids: Normal saline at 100 mL/hour.
12. Specialists or Consults: Request oncology and gastroenterology consults pending diagnostic outcomes.
13. Medications:
    - Acetaminophen 650 mg orally every 6 hours as needed for pain.
    - Ondansetron 4 mg intravenously every 6 hours as needed for nausea.
    - Ferrous sulfate 325 mg orally daily for presumed iron-deficiency anemia.
    - Reconcile home medications and discontinue non-essential drugs until
      further assessment.

Challenges in Existing Nursing Care

Dr.AI offers various solutions to address the following problems in nursing care:

- Nursing staff shortage
- Heavy nursing workload
- Insufficient continuity of patient care

- Insufficient nursing education and training
- Time-consuming and error-prone administrative and documentation work
- Increasing patient diversity and complexity

AI Medical Scribe for Nursing Note

From BMC Med Educ. 2020; 20(Suppl 2): 459.

You are the Intern in ED at a large teaching hospital, and it is 1130pm Friday. Mr. Smith is a 48 year old man who has been brought in by ambulance. This evening he became intoxicated at his local hotel, and on leaving the Hotel, fell down several concrete steps. Although still intoxicated, he is complaining of abdominal pain. Vital signs are all within the normal range.

Your examination reveals a large bruise on the left flank. The abdomen Is distended, and there is mild, diffuse abdominal tenderness. You suspect some shifting dullness, but as he is difficult to examine, you are uncertain. There is no hepato-splenomegaly, and bowel sounds are present. The only other positive finding is pitting oedema of both legs, below the knee.

He admits to a long history of alcohol abuse, and you suspect he may have cirrhosis with ascites, and you are concerned about possible traumatic hemoperitoneum, due to a torn or ruptured spleen.
You feel Mr. Smith needs an immediate abdominal ultrasound. The Registrar agrees & asks you to call the radiology Registrar to arrange for this to be done asap.

Nursing Note Generated by Dr.AI

Date: [Insert date here]
Time: 11:30 pm

SOAPIE

(Subjective) Mr. Smith, a 48-year-old man, complains of abdominal pain after falling down several concrete steps. He mentions a long history of alcohol abuse.
(Objective) On examination, Mr. Smith exhibits a large bruise on the left flank, abdominal distension, and mild, diffuse abdominal tenderness with no evidence of hepato-splenomegaly. Bowel sounds are present. Notable findings include pitting oedema of both legs, below the knee. Vitals are within normal range. The patient is still intoxicated, which complicates examination. Suspected shifting dullness observed, indicating possible ascites.
(Assessment) Given Mr. Smith's history of alcohol abuse and the current clinical findings, there is suspicion for cirrhosis with ascites. The abdominal trauma raises the concern for traumatic haemoperitoneum, possibly from a torn or ruptured spleen.
(Plan) An immediate abdominal ultrasound is deemed necessary to assess the extent of internal injury and to confirm the presence of ascites or haemoperitoneum.
(Implementation) Discussed the necessity of an abdominal ultrasound with the Registrar, who agreed with the assessment. Directed to arrange for an urgent abdominal ultrasound with the radiology department.
(Evaluation) Pending the arrangement and results of the abdominal ultrasound to inform further treatment plan. Continuously monitoring Mr. Smith’s condition and vital signs in the meantime.

Date: [Insert date here]
Time: 11:30 pm

ISBAR

(Introduction) I am [Your Name], an intern in the Emergency Department at [Hospital Name], providing an update on a patient currently under evaluation.
(Situation) Mr. Smith, a 48-year-old male, arrived by ambulance tonight after falling and sustaining injuries while intoxicated. He complains of abdominal pain and presents with several symptoms.
(Background) The patient has a history of chronic alcohol abuse, which may have contributed to underlying health issues such as cirrhosis. His injury tonight involved falling down concrete steps after leaving a hotel, leading to significant physical trauma.
(Assessment) Initial examination shows a large bruise on his left flank, a distended abdomen with diffuse tenderness, and shifting dullness, which complicates the diagnosis. There are no signs of hepato-splenomegaly, but the presence of pitting oedema and his symptoms suggest possible ascites and concerns about traumatic haemoperitoneum.
(Recommendation) It is critical to perform an immediate abdominal ultrasound to assess for internal bleeding or other complications from the suspected trauma. Coordination with radiology is necessary to expedite this diagnostic step.

https://youtu.be/PrxpxtpbMt0?si=a5Fi06RsvG2HDpLw

Meeting Recap

Meeting Date: [Insert Date]
Participants: Nerissa, [Others Not Listed]
Case ID: [Insert Case Identifier]
Patient Details:
- Age: 24
- Gender: Male

Discussion Points:

Symptom Overview:
- Bilateral pain in both knees
- Pain severity: 8 out of 10
- Pain worse upon standing and walking
- Reports chills and mild shortness of breath
- Denies fever, chest pain, nausea, vomiting, and abdominal pain

Past History:
- Sickle cell disease
- Stuttering priapism
- Lower extremity ulcers
- Last pain crisis: about a year ago
- Family history: Lives with his mom and four siblings, two of whom have sickle cell disease
- Social history: Social alcohol drinker, last weekend; does not smoke or use drugs

Present Illness:
- Pain onset: Two days ago during a night shift
- Pain not relieved by Percocet
- Intermittent left hand pain
- Normal vitals except for elevated heart rate (120) and low O2 saturation (89%)
- Physical exam:
  - Obvious discomfort, thin appearance
  - Normal heart sounds, clear lungs
  - Scaly rash on the flexor side of the elbow
  - Normal testes, no priapism
  - Right knee: mild swelling, small effusion, non-tender to palpation, tenderness on full extension
  - Left knee: no swelling or tenderness, full range of motion in both knees

Dr.AI swiftly generates meeting notes to enhance workflow and improve patient care by managing time effectively and minimizing errors

Assessment and Treatment Plans:
- Differential diagnosis: vaso-occlusive disease, periarticular infarct, septic arthritis, or gout
- Likely conditions: vaso-occlusive disease or periarticular infarct (afebrile)
- Tests ordered: Complete Blood Count (CBC), no x-ray deemed necessary
- Treatment:
  - NSAIDs for pain
  - Morphine for breakthrough pain
  - Monitoring for acute chest syndrome, splenic infarct, aplastic crisis, and splenic sequestration
  - Oxygen and fluids administration suggested due to low O2 saturation
  - Potential blood cultures and antibiotics if marked leukocytosis or fever develops

Clinical Decisions Made:
- Continue NSAIDs and morphine for pain management
- Administer oxygen and fluids immediately due to low O2 saturation
- Monitor for complications related to sickle cell disease
- Evaluate CBC results
- Consider blood cultures and antibiotics if signs of infection appear

Conclusions:
- Diagnostic reasoning emphasized the lower likelihood of gout due to the absence of characteristic symptoms and involvement of large joints.
- Discussion noted the anatomical consideration of vaso-occlusive events predominantly occurring in areas with limited arterial supply.
- Differential diagnosis centered on conditions related to sickle cell disease given the patient's history and presentation.
- Consensus to proceed with NSAIDs, morphine, oxygen, and fluid administration while closely monitoring the patient's condition over the next few days.
- Acknowledgment of a good presentation and the importance of detailed medical reasoning in complex cases.

2-2 Pain Points in Existing Outpatient Care

Challenges in Existing Outpatient Care

Dr.AI offers various solutions to address the following problems in outpatient care:

- Insufficient time for doctor-patient interaction
- Long patient waiting times and high doctor stress
- Blind spots in medical care



- Lack of interdisciplinary collaboration
- Time-consuming and error-prone documentation work
- Lengthy initial patient diagnoses

Generated from the Voice Recording of an Outpatient Consultation at the Clinic Through Dr.AI Medical Scribe

Through Dr.AI, doctors do not need to simultaneously type consultation notes and conduct examinations, allowing them to spend more time with the patient.

42-year-old Ms. Chen, where are you feeling unwell? Here, my upper abdomen has been hurting all night. Your upper abdomen has been hurting all night? Yes, and it’s uncomfortable to swallow. It hurts when I swallow, too. So it started last night? No, it started in the afternoon and continued into the evening. It’s been like this almost all day. Have you vomited? No. Have you had diarrhea? That's a good question because I’ve had diarrhea three times. OK, have you had any fever, headache, or muscle pain? No. Doctor, my stools are a bit stringy. Alright, let me check the area where your abdomen hurts. So, no fever? No. It hurts here in the upper abdomen? Yes. Does your waist hurt? Yes, here and here. What about lower down? No, just here and here. They say it’s the stomach. It does seem to be a stomach issue. When I swallowed a pill yesterday, it hurt here. It hurts when you swallow now, too? Yes, it does. That sounds like a stomach issue. When the stomach is inflamed, it can cause bloating, which makes you feel nauseous and can also cause pain. What is causing this? It could be acute gastroenteritis, sometimes caused by eating contaminated food or a viral infection. I have acute gastroenteritis? Yes, it’s gastroenteritis. Should I start eating porridge today? Eat bland foods like porridge. Avoid spicy and greasy foods, and don't consume dairy products like milk or soy milk for now. Can I only eat porridge? Yes, porridge, congee, or plain rice is fine. Try to eat some light vegetables, white toast, or steamed buns. So it’s acute gastroenteritis? Yes, it is acute gastroenteritis. Alright, I’ll prescribe some medication for you. Can you prepare the medicine as a powder for me? Sorry, we don’t have a grinder here. You’ll have to do it yourself. The clinic doesn’t have a grinder? No, we don’t. Alright, no problem. I’ll prescribe three days’ worth of medication. OK, thank you.

Outpatient SOAP Note Generated by Dr.AI

Subjective:
A 42-year-old female presents with symptoms of acute upper abdominal pain that started yesterday afternoon and persisted throughout the night. She reports that the pain worsens when swallowing food and has experienced diarrhea three times. No vomiting, fever, headache, or myalgia is reported. She also mentions that the pain radiates to her back but not to the lower abdomen.

Objective:
- Abdominal examination reveals tenderness in the epigastric region.
- No signs of fever or dehydration observed.
- Bowel sounds are present.
- No signs of chronic disease or distress noted.
- The presence of thread-like structures in stool may suggest possible inflammation or infection.

Assessment:
- Acute gastritis or gastroenteritis, likely due to foodborne illness or viral infection (ICD-10 Code: K52.9).

Plan:
1. Advise a bland diet, starting with porridge and avoiding spicy, oily foods, milk, soy milk, and other dairy products.
2. Prescribe medication for symptom relief and to manage inflammation.
3. Educate the patient on signs of dehydration and when to seek further medical attention.
4. Recommend over-the-counter antidiarrheal medication if necessary.
5. Follow-up in three days to assess progress. If symptoms persist or worsen, consider further diagnostic testing such as stool analysis or abdominal imaging.

Outpatient Labs and Exam

Gender：Male
Date of birth：1969/08/09
Blood type & Rh factor：O+
Marriage status：Married
Give birth：Yes
Smoking：Secondhand smoke
Alcohol：heavy
Betel nut chewing：No
Coffee：No
Daily working hours：10Hour(s)
Sleeping time：7Hour(s)

Medical History:
Hyperlipidemia
Hypertension
Gout
Chronic Hepatitis B
Ulcerative colitis

Medication History & Nutritional Supplements:
Anti-hypertensive drugs
Lipid lowing drugs
Glucose lowing drugs
Multivitamin
Probiotics

Family History:
Diabetes
Hypertension
Coronary Heart Disease
Colorectal cancer, Anal cancer
Gastric cancer

Date of Exam：2020/04/03

General Data & Physical Exam		
Physical Exam		
Body height	170	cm
Body weight	67	kg
BMI (WHO classification)	23.2	Kg/m2
Body fat composition	23 %	
Cardiovascular System		
Systolic BP	145	mmHg
Diastolic BP 90	mmHg	
Cardiac Enzyme		
CPK	300	U/L
Respiratory System		
Tumor Markers		
CEA	3 ug/L	
Digestive System		
AST (GOT)	35	U/L
ALT (GPT)	30	U/L
Albumin	4.2	g/dL
Globulin	2.1	g/dL
Total protein	6.3	g/dL
γ-GT	150	U/L
Direct bilirubin	0.3	mg/dL
Indirect bilirubin	1.6	mg/dL
Total bilirubin	1.9	mg/dL
IgG anti-HAV	(+)	S/CO
HBsAg	(+)	Index
Anti-HBs	(-)	mIU/mL
HBeAg	(+)	S/CO
Anti-HBe	(-)	S/CO
HBV DNA	25000	IU/mL
Anti-HCV	(-)	Index
UBT	12(+)	DOB
α-FP(Alpha-Fetoprotein)	16 ug/L	
CEA	3	ug/L
Endocrine System		
Total Cholesterol	280	mg/dL
Triglyceride	240	mg/dL
HDL-Cholesterol	67	mg/dL
LDL-Cholesterol	165	mg/dL
Glucose AC	105	mg/dL
HbA1C	6.1	% of Hb
TSH	4	mU/L
Free T4 1.3	ng/dL	
Uric acid	8	mg/dL
Immune System		
ANA	80(+)	
Urinary System		
BUN	24	mg/dL
Creatinine	1.2	mg/dL
Protein in urine	(+/-)	
Urine occult blood	(++)	
Musculoskeletal System		
RBC	4.5	10E6/uL
Hemoglobin	13	g/dL
Platelet	208	10E3/uL

Date of Exam：2021/04/12

General Data & Physical Exam		
Body height	170	cm
Body weight	69	kg
BMI (WHO classification)	23.9	kg/m2
Body fat composition	26	%
Cardiovascular System		
Systolic BP	150	mmHg
Diastolic BP	96 mmHg	
CPK	150	U/L
Respiratory System		
CEA	6 ug/L	
Digestive System		
AST (GOT)	88	U/L
ALT (GPT)	130	U/L
Albumin	4.5	g/dL
Globulin	2.4	g/dL
γ-GT	250	U/L
Direct bilirubin	1.5	mg/dL
Indirect bilirubin	1.5	mg/dL
Total bilirubin	3	mg/dL
HBsAg	(+)	Index
HBeAg	(+)	S/CO
Anti-HCV	(+)	Index
HCV RNA	25385(+)	IU/mL
UBT	(+)	DOB
Immunochemical fecal occult blood test	125 ng/mL	
Guaiac fecal occult blood test	(+)	
α-FP(Alpha-Fetoprotein)	55	ug/L
CEA	6	ug/L
Endocrine System		
Total Cholesterol	290	mg/dL
Triglyceride	250	mg/dL
HDL-Cholesterol	70	mg/dL
LDL-Cholesterol	170	mg/dL
Glucose AC	128	mg/dL
HbA1C	6.6	% of Hb
Uric acid	6	mg/dL
Urinary System		
BUN	20	mg/dL
Creatinine	1.5	mg/dL
Musculoskeletal System		
RBC	3.5	10E6/uL
Hemoglobin	11	g/dL
MCV	70	fl
Platelet	170	10E3/uL
Serum iron	15	ug/dL
TIBC	400	ug/dL
Ferritin	10	ng/mL

Date of Exam：2022/04/28

General Data & Physical Exam		
Body height	170	cm
Body weight	72	kg
BMI (WHO classification)	24.9	kg/m2
Body fat composition	28	%
Cardiovascular System		
Systolic BP	120	mmHg
Diastolic BP	80	mmHg
Respiratory System		
CEA	3.2	ug/L
Digestive System		
AST (GOT)	30	U/L
ALT (GPT)	36	U/L
γ-GT	150	U/L
Direct bilirubin	0.3	mg/dL
Indirect bilirubin	1.5	mg/dL
HBsAg	(+)	Index
HBV DNA	0	IU/mL
Anti-HCV	(+)	Index
HCV RNA	0	IU/mL
UBT	3 (-)	DOB
Guaiac fecal occult blood test		(-)
α-FP(Alpha-Fetoprotein)	380	ug/L
CEA	3.2	ug/L
Endocrine System		
Total Cholesterol	150	mg/dL
Triglyceride	100	mg/dL
HDL-Cholesterol	20	mg/dL
LDL-Cholesterol	110	mg/dL
Glucose AC	80	mg/dL
HbA1C	5.8	% of Hb
TSH	0.01	mU/L
Free T4	2.5	ng/dL
Uric acid	8	mg/dL
Immune System		
anti-HIV	(-)	<1.00
	S/CO	
ANA	160(+)	
Urinary System		
Creatinine	2.5	mg/dL
Urine occult blood	(+)	
Urine microalbumin	200	mg/L
Musculoskeletal System		
RBC	5.8 10E6/uL	
Hemoglobin	13.5	g/dL
Platelet	200	
	10E3/uL	
Serum iron	50	ug/dL
TIBC	220	ug/dL
Ferritin	50	ng/m

Outpatient CPMP (Comprehensive Personal Medical Profile, by Dr.AI)

Impression 1: Chronic Hepatitis B and C with a high possibility of Liver Disease

Evidence-Based on: Consistent detection of hepatitis B surface antigen (HBsAg) and hepatitis E antigen (HBeAg), high levels of hepatitis B virus (HBV) DNA, presence of anti-HCV antibodies, and elevated HCV RNA in 2021. Elevated liver enzymes (AST, ALT, γ-GT) are indicative of ongoing liver inflammation.

Interpretations and Suggestions: Your lab results suggest a chronic dual infection with hepatitis B and C, both of which could have contributed to a state of chronic liver inflammation, potentially progressing towards cirrhosis or even liver cancer. The drastically elevated alpha-fetoprotein (AFP) in 2022 is a worrying sign and might be indicative of hepatocellular carcinoma (HCC). Please ensure to undergo regular liver function tests, and further investigate the elevated AFP via imaging. An antiviral treatment regimen should be initiated if not yet started to control the hepatitis virus activity.

Impression 2: Persistent Hyperlipidemia

Evidence-Based on: Sustained high levels of total cholesterol, triglycerides, and LDL cholesterol over the years, despite taking lipid-lowering medication.

Interpretations and Suggestions: Your lipid levels remained high until 2022, suggesting a lack of control despite medication. This could be due to either inadequate dosing, non-compliance, or resistance to treatment. You should ensure proper adherence to your medication schedule and consider lifestyle modifications such as dietary improvements, increased physical activity, and reduction in alcohol consumption to aid in controlling your lipid levels.

Impression 3: Controlled Hypertension

Evidence-Based on: Initially elevated systolic and diastolic blood pressure readings which normalized by 2022, suggesting effective treatment with anti-hypertensive medication.

Interpretations and Suggestions: Your blood pressure control seems to have improved by 2022, suggesting that your current antihypertensive treatment is effective. Please continue your medication as prescribed and maintain regular blood pressure checks. Complementary lifestyle modifications including a balanced diet, regular exercise, and moderation in alcohol consumption should be maintained for optimal control.

Impression 4: Suspected Diabetes Mellitus

Evidence-Based on: Elevated fasting glucose and HbA1c levels in 2021, which normalized in 2022, along with the prescription of glucose-lowering medication.

Interpretations and Suggestions: The glucose and HbA1c levels from 2021 suggest possible diabetes mellitus which seems to be under control in 2022. Regular blood glucose monitoring and HbA1c tests are essential to ensure continued control of your blood sugar levels. Lifestyle modifications including a balanced diet, regular physical exercise, and weight management are crucial to maintaining control over your blood glucose levels.

Impression 5: Potential Renal Dysfunction

Evidence-Based on: Gradual elevation of creatinine levels over the years, along with the detection of occult blood and microalbuminuria in the urine in 2022.

Interpretations and Suggestions: Your lab results suggest potential kidney dysfunction. Elevated creatinine levels and the presence of both blood and albumin in your urine are indicative of kidney damage. Regular renal function tests, control of blood pressure, and reduction in alcohol consumption are necessary to prevent further deterioration of your kidney function.

Impression 6: Potential Hyperthyroidism

Evidence-Based on: Low thyroid-stimulating hormone (TSH) levels and high free thyroxine (Free T4) levels in 2022.

Interpretations and Suggestions: The thyroid function tests from 2022 suggest potential hyperthyroidism. Further assessment of your thyroid function and consultation with an endocrinologist may be required to determine the need for treatment and to control potential with content that is not suitable for display on this platform.

Impression 7: Potential Iron-deficiency Anemia

Evidence-Based on: Low hemoglobin, serum iron, and ferritin levels, along with high TIBC in 2021.

Interpretations and Suggestions: You should consider supplementation with iron, coupled with diet modification to include iron-rich foods, and consider further workup for the cause of iron-deficiency anemia.

SOAP Note by MedPA Pro

Medical Pre-Assessment Chatbot

Features of MedPA Pro:
During patient registration, MedPA can be placed at the check-in counter to perform pre-consultation. The voice recording with AI QA interaction will be sent to the doctors' backend workspace to immediately generate medical records and SOAP notes. This process makes it easier for doctors to preview patients' subjective information and symptoms before the patient walks in, saving tremendous consultation time

Subjective: The patient reports pain in the lower right abdomen, which started yesterday and has worsened today. The pain is exacerbated by pressing on the abdomen and is only slightly relieved by rest, continuing as a constant ache. Symptoms include a mild fever and nausea without vomiting, with a loss of appetite. The patient has a history of hypertension and is currently taking diuretics. No surgical history. Allergic to certain antibiotics like penicillin. The patient mentioned stress-related sleep deprivation and a family history of thyroid disease on the maternal side and coronary artery disease on the paternal side.

Objective: Current symptoms suggest a possible infection or inflammation, indicated by fever and localized pain. Allergies should be noted for medication safety.

Assessment: Considering the symptoms, a preliminary diagnosis of appendicitis is considered. Differential diagnosis includes gastrointestinal issues or urinary tract problems. An ICD-10 code for acute appendicitis is K35.

Plan: Recommend immediate further diagnostic testing to confirm appendicitis, including an abdominal ultrasound or CT scan. Blood tests for infection markers and a consultation with a specialist in gastrointestinal disorders may be necessary. Ensure allergy profile is checked before any antibiotic prescription. Address sleep issues and stress management as part of long-term well-being.

2-3 Solutions Applicable to Exam Report Documentation

Dr.AI Med Report Pro

Endoscopy: Colonoscopy, EGD, Nasopharyngoscopy, …

Ultrasound: Abdominal, Thyroid, Carotid, Cardiac, Breast, GYN, …

Intraoperative Recording: Laparoscopy, Open surgery, …

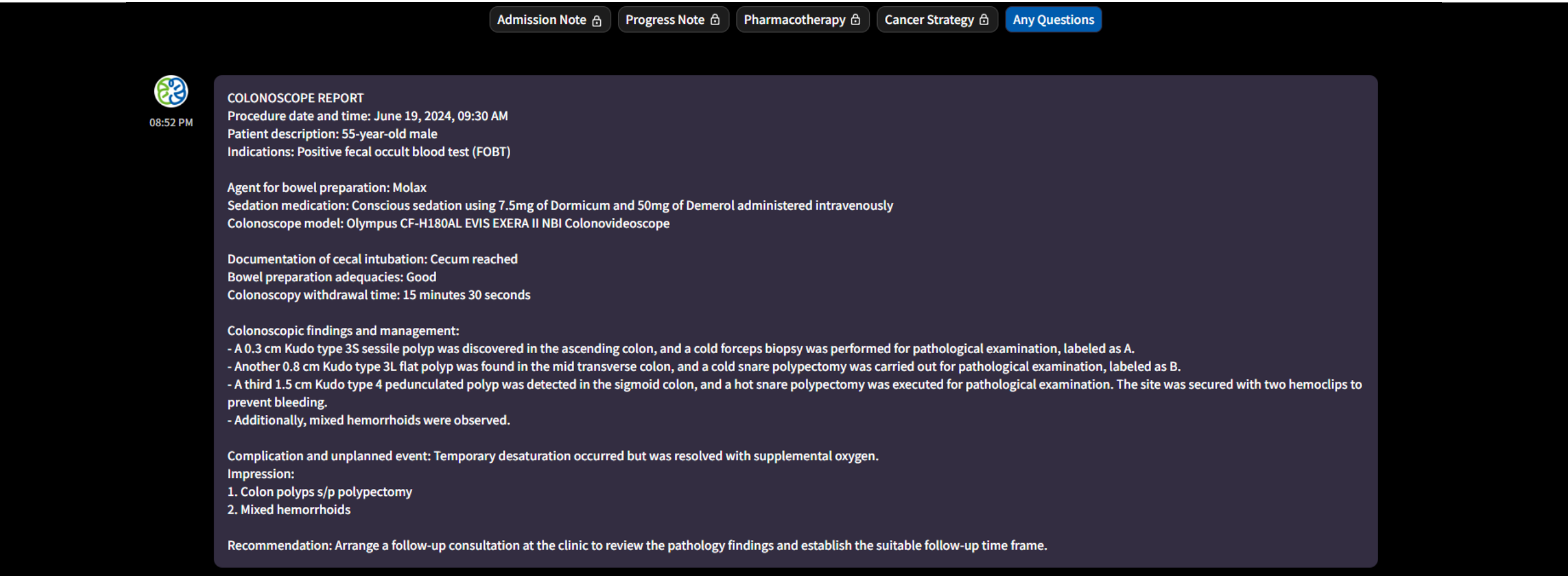

3. Dr.AI for the General Public

Dr.AI

AI Router – MoAI (Healthcare Chatbot)

In collaboration with Gemtek, we have launched the WiFi 7 AI Router MoAI, featuring the voice assistant Dr.AI. This router provides not only high-speed internet connectivity but also health consultations via voice interactions

5. Dr.AI MedExam Pro for Health Examination Centers

Dr.AI Health Exam Report Generation System

Dr.AI

High Efficiency and High Quality

- **Generate 100 reports in just 15 minutes**

By significantly optimizing your workflow, it saves valuable time and enhances the capacity of your medical services.

- **No need for manual template retrieval**

Dr.AI MedExam Pro generates reports directly from examination results, eliminating the need to manually retrieve pre-written templates. It provides personalized comprehensive diagnostic advice.

- **Comprehensive diagnostics across 12 specialized fields**

Offers comprehensive and accurate narrative diagnostics and advice. These diagnostics include individualized follow-up recommendations based on real-time cross-analysis of medical data.

- **Cross-analysis integrating three elements for comprehensive evaluation**

Analyzes medical history and family history, lifestyle habits, and abnormal values.

Customizable Report Modules

Based on the needs of medical exam centers, it offers multiple report modules to choose from, offering Basic, Plus, and Premium versions, and further customizes the required formats and content.

Basic Report

Suitable for single, simple physical examination items such as general physical exams, labor inspections, and initial health check-up packages. Provides a brief analysis along with AI comprehensive diagnosis and a nutrition instruction report.

Plus Report

Ideal for health check-up packages that include comprehensive physical examinations and specific screening items such as imaging studies. Offers detailed analysis and multiple explanatory reports along with AI comprehensive diagnosis and a nutrition instruction report.

Premium Report

Perfect for high-value health check-up packages that may include advanced imaging or VIP packages. Provides detailed and comprehensive AI diagnostic analysis along with a nutrition instruction report.

Exclusive Three Value-Added Plans Provided

The checkup report includes value-added dietary recommendations, supplement suggestions, and lifestyle medicine advice

Dietary Recommendations

Diet Suggestions:

- Incorporate a high fiber diet with plenty of fruits, vegetables, whole grains, and legumes to manage prediabetes and hyperlipidemia, and to aid in weight loss.
- Choose lean protein sources and healthy fats, such as fish rich in omega-3 fatty acids, to support heart health.
- Limit intake of salt and processed foods to help control blood pressure.
- Avoid foods high in refined sugars and carbohydrates to help manage blood glucose levels.
- Opt for low glycemic index foods to stabilize blood sugar.
- Ensure adequate hydration throughout the day.

Supplement Suggestions

Supplement Recommendations:

- Consider a daily multivitamin that does not exceed 100% of the Daily Value of iron, unless otherwise directed by your physician, due to Thalassemia Minor.
- Omega-3 fatty acids supplement could be beneficial for heart health.
- A Vitamin D supplement may be beneficial, especially if your lifestyle or geographic location limits sun exposure.
- Magnesium supplements could help in managing hypertension and might assist in improving sleep quality.

Lifestyle Medicine Suggestions

Lifestyle Medicine Suggestions:

- Adopt a whole-food, plant-predominant eating pattern focusing on nutrient density to support weight management, improve lipid profile, and manage blood sugar levels.
- Engage in regular physical activity, aiming for at least 150 minutes of moderate aerobic exercise per week, along with muscle-strengthening activities on two or more days per week. This will aid in managing obesity, hypertension, and prediabetes.
- Ensure restorative sleep by maintaining a consistent sleep schedule, creating a sleep-conducive environment (cool, dark, and quiet), and avoiding stimulants and screens before bedtime.
- Manage stress effectively through mindfulness techniques, such as meditation, deep breathing exercises, or yoga. These practices can help in reducing blood pressure and improving overall well-being.
- Avoid risky substances by limiting alcohol consumption and avoiding smoking or the use of illicit drugs. Given Gilbert's Syndrome, minimizing alcohol intake is particularly important to avoid additional liver stress.
- Foster positive social connections by maintaining close relationships with friends and family. Participating in community or group activities that interest you can also provide emotional support and improve mental health.

Implementation Achievements

Dr. AI MedExam Pro has been adopted by Fu Jen Catholic University Hospital and Lotung Poh-Ai Hospital and is being integrated into their health checkup report systems to optimize health checkup care processes.

	Fu Jen Catholic University Hospital	Lotung Poh-Ai Hospital
Established	Established: September 29, 2017	1953
Type	University Hospital	General Hospital
Scale of Medical Services	• Inpatient: 656 beds (as of August 2022)	• Inpatient: 753 beds
Remarks	• Implementation approved by the hospital and university medical school	

Dr.AI

Start for free now!

Please feel free to contact us,
if you have any inquiries.

sales@draiai.com

www.draiai.com